



PATIENT

Bonnie Hough

SPECIES

Canine

BREED

Great Dane

SEX

FS

AGE

6 years

WEIGHT

121 lbs

INTERPRETED BY

Maggie Machen Lamy, DVM, DACVIM (Cardiology)

IMAGING PERFORMED BY

Sara Hansen, SDEP
Clinical Sonographer

HOSPITAL NAME

Countryside Animal Clinic

REFERRING VET

Dr. Cox

INVOICE

27674

DATE

11/28/22

PRESENTING CLINICAL SIGNS

History: Grade 2-3/6 systolic heart murmur. Pt had a cervical slot surgery at the beginning of the month and is now experiencing an increased RR and labored breathing overall

Abnormal PE/Chem/CBC/UA Results: 130 HR 30 RR Blood Pressure Measurements n/a Current Medications Methocarbamol 500mg Tablet, Vetprofen 100mg Caplet, Gabapentin 300mg Capsule, Trazodone 100mg Echocardiogram results: DCM-phenotype, rec quadrotherapy

ELECTROCARDIOGRAPHIC FINDINGS *Note: Single lead ECGs are evaluated as a rhythm strip.

Morphology/MEA cannot be definitively commented on.

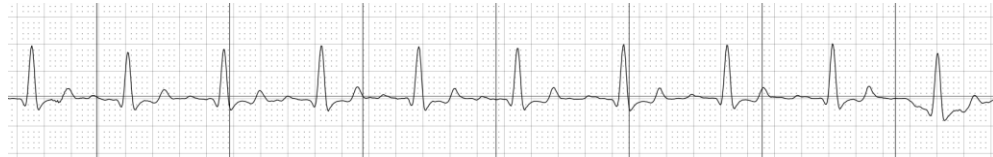
A single lead ECG is available; 50mm/s, 10mm/mV. The average heart rate is 170bpm (range 166-176bpm). The rhythm is sinus in origin, with a p for every QRS complex and vice versa. The P and QRS morphologies are positive. No ectopic beats, pauses or dysrhythmias observed.

ECG diagnosis: Normal sinus tachycardia.

INTERPRETATION OF THE FINDINGS & FURTHER RECOMMENDATIONS

Unremarkable tracing with a normal sinus tachycardia, likely secondary to stress and suspect CHF. No follow up is necessary unless an irregular rhythm is noted on exam, or signs of arrhythmias develop (syncope, acute lethargy). This signalment is highly predisposed to both rapid atrial fibrillation and malignant ventricular arrhythmias, and periodic monitoring is advised.

IMAGES



The information and recommendations provided are based on the images presented by the referring veterinarian. No evaluation can be communicated regarding pathology that was not visible in the image/video clips provided.

Thank you for this referral. If the clinical or image interpretation does not parallel your findings or if I can be of any further assistance, please contact me.

Maggie Machen Lamy, DVM
Diplomate of the American College of Veterinary Internal Medicine (Cardiology)
info@sonopath.com